

T2 Star Weighted ANgiography (SWAN)

SWAN is a helpful diagnostic tool that clearly delineates small blood vessels, microbleeds, and large vascular structures in the brain. It is also designed to visualize iron and calcium deposits.

Technically, SWAN applies a multi-TE readout technique that generates more than double signal-to-noise ratio and is less affected by the chemical shift compared to conventional SWI techniques. Because of the novel technology it generates high resolution 3D dataset that integrates a broad range of distinct tissue contrasts with significantly enhanced susceptibility information, and signal-to-noise ratio. In this system, the acquisition of the entire brain with 3D, sub-millimeter resolution takes approximately four minutes, and image reconstruction is instantaneous.

It generates fantastic images of the microbleeds coupled with a good contrast.

Neuro MRI: Utility of SWAN in picking CT occult calcifications

Dr. Chandramouly

Clinical Director
Lucid Medical Diagnostics, Bangalore



"SWAN is a consistent technique that helps in depicting brain vasculature as well as calcifications"

Patient History

A 38-year-old woman presented with persistent headache that had lasted for a month. She had an episode of seizure in her teens which was repeated recently. She complained of an anxious feeling occasionally. No other relevant family or past medical history.

Physical examination

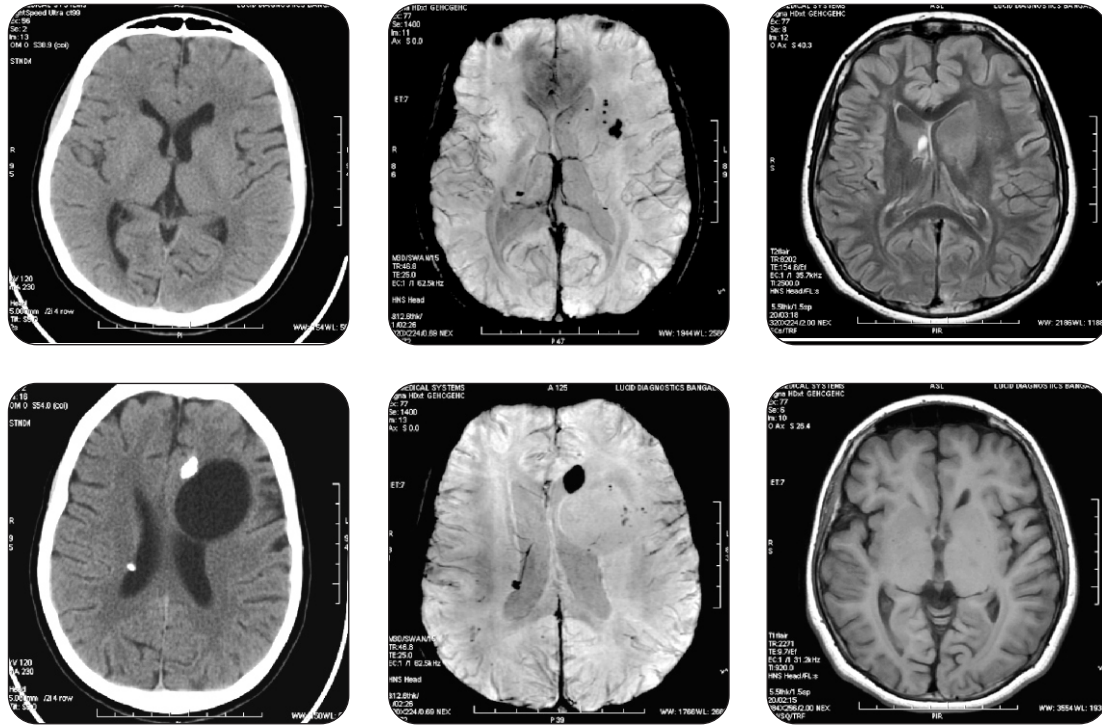
- Weakness in the muscles of the lower limb was seen
- The patient had difficulty in balance and coordination
- Evidence of psychiatric illness (anxiety)

Provisional diagnosis

- Calcification/tumour growth in the brain, ? Fahr's syndrome

MRI technique and Findings

Axial SWAN images were obtained to look for calcification or bleed. Routine brain MRI protocol with Axial T2, T2 Flair, T1, DWI, Sag CUBE was performed. On radiological examination, multiple small variable sized signal intensities suggestive of calcified tubers were observed.



Images courtesy of Lucid Medical Diagnostics, Bangalore

Treatment

Control of calcium levels in the blood using pharmacological and diet therapy. Treatment of seizures with antiepileptic medication and psychiatric consultation for anxiety symptoms.

Conclusion

SWAN helps in the correct diagnosis of calcifications in the brain.

"This article has been published by GE Healthcare with consent of the authors/institutions concerned in academic interest. The views expressed in the case study are solely those of the Author. For circulation within India only"

To learn more about GE MRSystems SMS **GEHC to 56677** or call our toll free number at **1800 209 9003** or email to **dhrumil.sorathia@ge.com**



imagination at work