GE Healthcare

Epidermoids in uncommon locations (eg, intraparenchymal tumors) can pose a significant diagnostic challenge and could be misdiagnosed as astrocytomas preoperatively. MR imaging is the best modality for evaluating these tumors. Characteristically, these lesions are either isointense or slightly hyperintense relative to CSF on T1- and T2-weighted images. The distinction is usually made with FLAIR and DW imaging. Arachnoid cysts follow the signal intensity patterns of CSF with all MR pulse sequences, whereas epidermoids are not hypointense on FLAIR images and display areas of hyperintense signal relative to CSF. On DW images, epidermoids typically show restricted diffusion, unlike arachnoid cysts. Finally, although most epidermoids do not enhance, up to 25% may show minimal rim enhancement. Although most epidermoids have a fairly typical appearance and can be diagnosed with the above-mentioned criteria, their signal intensity characteristics may vary depending on the amounts of cholesterol and keratin within the tumor.

Routine application of eDWI in spine along with FIESTA 3D in appropriate cases may aid the radiologist in giving appropriate diagnosis and thereby helping patients and the clinicians in arriving at appropriate diagnosis.

A case of

Epidermoid Tumor of the Thoracic Spine– Role of eDWI and 3D FIESTA

Dr. Sharath Kumar, MBBS, MD, DM
Consultant Neurointerventional Radiologist
Department of Radiodiagnosis and
Interventional Radiology,
Apollo Speciality Hospital, Bangalore -560011.

"eDWI and 3D FIESTA are effective complementary diagnostic tools in characterization of intramedullary spinal cord pathologies"

Patient history

- A patient presented to the department of neurosurgery with the history of progressive paraparesis since 2 years.
- MRI was done many times during this period and could not arrive at any diagnosis.
- Repeat MRI was done and the patient was diagnosed with dorsal cord epidermoid tumour having an exophytic component
- Histopathology confirmed the radiological diagnosis
- Patient was operated and is recovering well

Findings

This case is unusual for several reasons. This patient did not have congenital anomalies and the tumor was located in the thoracic spine. The tumor had an unusual exophytic component and was not diagnosed since 2 years due to lack of specific imaging features. eDWI was not utilised in any of the previous imaging techniques and hence this case shows the importance of routine application of eDWI in spine imaging. The exophytic component was not obvious in the routine sequences and was only seen on FIESTA 3D imaging. This case report also shows the importance of 3DFIESTA in characterising the lesion.

imagination at work

FIGURE 1 **FIGURE 2** **FIGURE 3**

Figure 1. T2W sagittal image shows intramedullary well defined rounded hyperintense lesion at D5-6 level.

Figure 2. T1W sagittal image shows intramedullary well defined rounded hypointense lesion at D5-6 level.

Figure 3. STIR sagittal image shows intramedullary well defined rounded hyperintense lesion at D5-6 level.

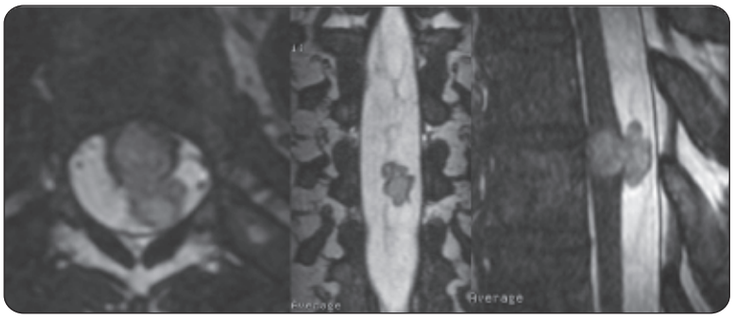

3D FIESTA acquired in sagittal plane and reconstructed in axial and coronal planes, all showing intramedullary mildly hyperintense lesion with large dorsal exophytic component

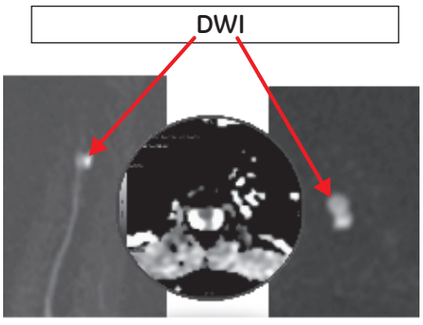

eDWI and corresponding ADC images showing restriction in the lesion

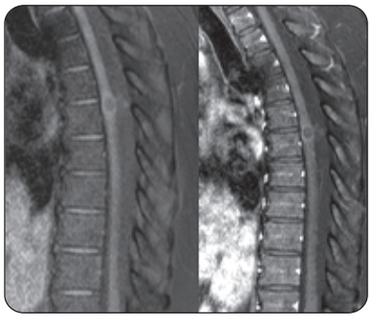

Pre and post contrast -T1WI showing no significant enhancement of the lesion

Treatment

Treatment of such cases is surgical excision. Patient was operated successfully and tumor was excised completely without any complications. Repeat MRI with DWI showed complete resection of the lesion.

Conclusion

eDWI along with FIESTA 3D is an excellent complementary diagnostic tool for spinal imaging.