

## 3D MRCP

3D MRCP is a technique that provides clear delineation of pancreatico-biliary ductal system with appropriate background suppression. This is a robust method which should be routinely used in all patients with recurrent pancreatitis and for congenital malformation of pancreatico-biliary ductal system. It delivers promising results even in unco-operative patients with severe pain and children due to its short scan time.

# Utility of 3D MRCP in abdominal conditions

**Dr. Vivek Gupta, MD**

Consultant Radiologist

Dr. Sameer Pusalkar's Imaging Centre  
Bhopal, India



"3D MRCP is an excellent technique for diagnosis of abdominal conditions"

### CASE 1

#### Patient history

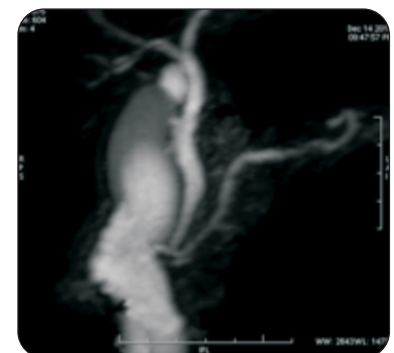
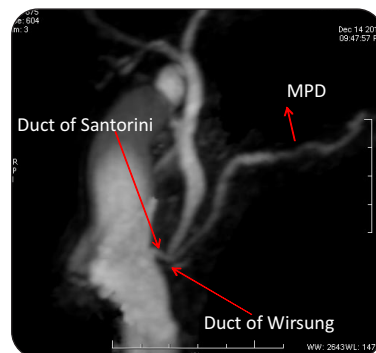
A 23-year-old male presented with complaints of recurrent pancreatitis.

#### Technique & findings

MRCP protocol was used, which included Axial T2 FRFSE, COR SSFSE, Axial SSFSE, Coronal FIESTA and 3D MRCP.

Routine MR sequence showed changes of acute pancreatitis.

3D MRCP showed abnormal dilatation of duct of Santorini draining into the MPD. The duct of Wirsung appeared smaller. These findings were suggestive of pancreatic divisum.



3D MRCP



## CASE 2

### Patient history

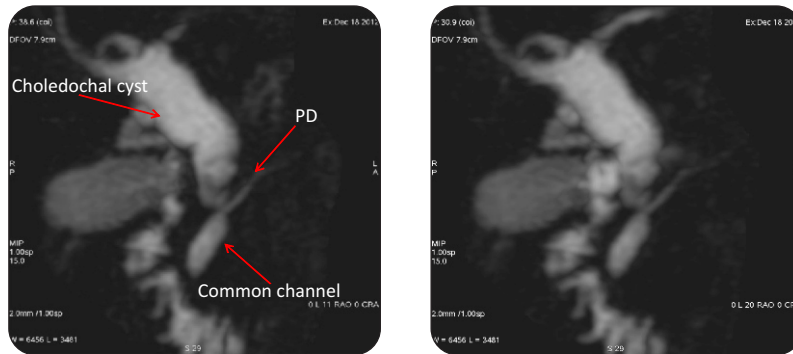
A 5-year-old child presented with complaints of abdominal pain. The USG of abdomen showed dilated CBD.

### Technique & finding

The MRCP protocol was used which included Axial T2 FRFSE, COR SSFSE, Axial SSFSE, Coronal FIESTA and 3D MRCP.

Routine MR sequence showed dilated CBD with no other abnormality.

3D MRCP showed abnormal dilatation of the entire CBD and CHD with normal appearing intrahepatic ducts. There was abnormal higher insertion of the MPD and CBD with a common channel draining into duodenum. Findings were suggestive of Type 1a Choledochal cyst with higher insertion of MPD and CBD as predisposing factors.



3D MRCP

Image courtesy to Dr. Sameer Pusalkar's Imaging Centre, Bhopal, India

"This article has been published by GE Healthcare with consent of the authors/institutions concerned in academic interest. The views expressed in the case study are solely those of the Author. For circulation within India only"

To learn more about GE MR Systems SMS **GEHC** to **56677** or call our toll free number at **1800 209 9003** or email to **dhruvil.sorathia@ge.com**



imagination at work