

Inhance Venio

Radiologist's opine that as compared to 2-D TOF venogram sequence, the Inhance sequence depicts the venous structures, particularly the smaller peripheral vessels to an exquisite detail. This detailing is due to better background suppression. The arteries and veins are also clearly depicted. For the diagnosis and imaging of vascular malformations in the pediatric age group, use of this single sequence is recommended. The acquisition time of this technique is less than angio and veno acquired separately.

Use of Inhance Venio for Diagnosis of Vein of Galen Malformation

Dr. Sameer Pusalkar, MD

Director

Dr. Sameer Pusalkars Imaging Centre,
Bhopal, India



"Inhance Venio is a superior diagnostic technique for depiction of vein of Galen malformation"

Patient history

- One day old male baby.
- The baby developed seizures.
- Antenatal ultrasound showed prominent midline venous structures.

Physical examination

On examination the patient showed-

- Tachypnoea
- Hypoxia
- Cardiomegaly

MRI technique and findings

Routine MRI VENIO protocol includes Diffusion, T2 Axial and Inhance venio images.

T2 weighted images showed aneurysmal dilatation of the midline venous structures, straight sinus, transverse sinuses, sigmoid sinuses and Torcula herophila. No Nidus or parenchymal AVM were noted.

These findings were confirmed using Inhance MR venio.



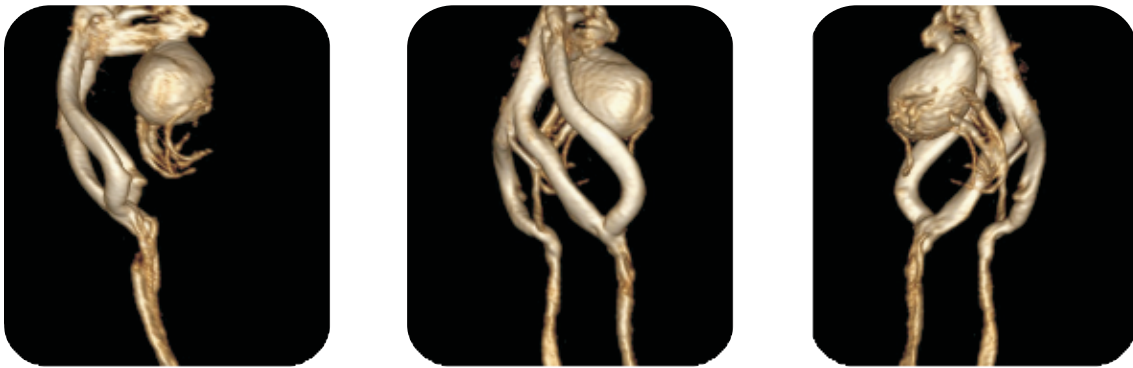

Fig. 1: VR images

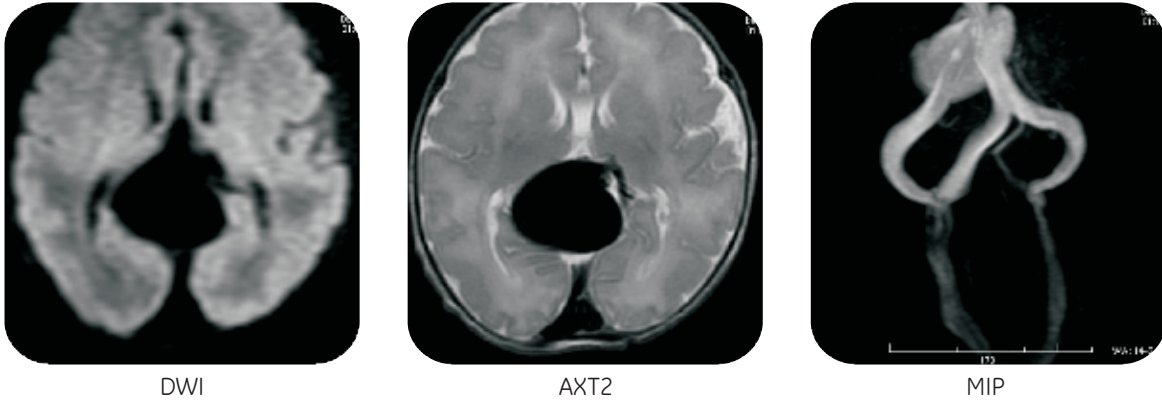


Fig. 2: T2 weighted images

Image courtesy to Dr. Sameer Pusalkars Imaging Centre, Bhopal, India

"This article has been published by GE Healthcare with consent of the authors/institutions concerned in academic interest. The views expressed in the case study are solely those of the Author. For circulation within India only"

To learn more about GE MR Systems SMS GEHC to 56677 or call our toll free number at 1800 209 9003 or email to dhruvil.sorathia@ge.com



imagination at work